

## **ABDOMINAL AORTIC ANEURYSMS**

**Chuo Ren Leong, Rajeev Gupta, Mark Kissin**

*Long Island Jewish Medical Center, New Hyde Park, New York, U.S.A.*

**Robert W. Chang**

*The Permanente Medical Group, South San Francisco, California, U.S.A*

**John B. Chang**

*Long Island Jewish Medical Center, New Hyde Park, New York, U.S.A.*

**Keywords:** aortic aneurysm, aneurysm disease, open aortic repair, endovascular repair, stent graft, surgical technique

### **Contents**

1. Introduction
  - 1.1. Historical Background
  - 1.2. Abdominal Aortic Aneurysms
  - 1.3. Anatomy
  - 1.4. Pathophysiology
  - 1.5. Etiology
  - 1.6. Diagnosis
  - 1.7. Surgical Treatment
  - 1.8. Indications for Repair
  - 1.9. Open Repair
  - 1.10. Endovascular Repair of Abdominal Aortic Aneurysm
  - 1.11. Open Arterial Access Technique
  - 1.12. Endovascular Repair of Proximal Abdominal Aortic Aneurysm
  - 1.13. Iliac Conduit for EVAR for Severe Occlusive Disease at the External Iliac Arteries
  - 1.14. Fenestrated Stents
  - 1.15. Branched Stents
  - 1.16. Non-Resective Repair of AAA (Hacker et al 2011)
  - 1.17. Recent Studies
  - 1.18. Short Term Results of EVAR
  - 1.19. DREAM Trial (Prinssen et al 2004)
  - 1.20. DREAM Follow-Up (Blakensteijn et al 2005)
  - 1.21. Dream Update (De Bruin et al 2010)
  - 1.22. EVAR 1 Trial (Greenhalgh et al 2004)
  - 1.23. EVAR 1 Trial Follow-Up (Greenhalgh et al 2005)
  - 1.24. EVAR 1 Long-Term Results (Greenhalgh et al 2010)
  - 1.25. EVAR 2 Trial (EVAR trial participants. 2007)
  - 1.26. Eurostar Registry (Harris et al 2000; Laheij et al 2000)
  - 1.27. Current FDA-Approved Endografts for AAA:
  - 1.28. Personal Data
  - 1.29. Endovascular Repair of an Iliac Artery Aneurysm
  - 1.30. Endovascular Procedures in Azotemic Condition Using CO<sub>2</sub>.

### 1.31. Conclusion

Glossary

Bibliography

Biographical Sketches

## Summary

Abdominal aortic aneurysm is most common in the position of infra-renal aorta. It is most common among the elderly population. The definition of aortic aneurysm is a permanent focal dilatation of the aortic wall, at least twice the size of a person's normal aortic diameter. Diagnosis of an abdominal aortic aneurysm is made by physical examination, confirmed by ultrasound, CT scan, and sometimes with MRA and an angiogram, for elective repair before a catastrophic rupture. Repair of an abdominal aortic aneurysm can be done by standard open surgical techniques, endovascular repair, and in rare cases, using an unusual approach of non-resective repair. It is important to detect this disease before rupture, and the ability for elective repair to reduce surgical morbidity and mortality.

## 1. Introduction

Arterial aneurysms are one of the most common vascular disease causes of disability and death. Although it occurs in most arteries throughout the body, it is most common in the infrarenal abdominal aortic portion and is particularly common in the elderly. The definition of an aneurysm is a permanent focal dilation of an artery of at least 50% increase in diameter compared to the expected normal diameter of the artery in question.

Aneurysms are further classified into true versus false aneurysms. The former involves all three layers of the arterial wall while the latter involves a portion of the arterial wall with presence of blood flow outside the normal layers of arterial wall. False aneurysms (or pseudoaneurysms) are associated with complications from needle punctures, infections, or arterial anastomotic disruption, and lacks three true layers of the aneurysm wall.

### 1.1. Historical Background

The history of the treatment of aortic aneurysms can be traced as far back as the 2nd century AD, where Antyll, performed proximal and distal ligation of aneurysms, thus providing the first record of the cause and treatment of aneurysms. Vesalius first diagnosed an abdominal aortic aneurysm (AAA) in 1555 and the great British surgeons John and William Hunter performed multiple ligations of peripheral aneurysms. In 1817 Astley Cooper was the first to ligate the abdominal aorta for a ruptured iliac aneurysm. In 1888, Rudolph Matas performed the first definitive repair, known as endoaneurysmorrhaphy, by ligating the branches of a brachial artery aneurysm from inside the aneurysm sac.

In 1951 Dubost managed to preserve blood flow during aneurysm repair when he replaced an abdominal aortic aneurysm with a thoracic aortic homograft. Cooley and DeBakey followed several months later in the United States. In 1954, Blakemore and

Voorhees published their series of aortic aneurysms repaired with Vinyon “N” cloth. Their work launched the modern age of using synthetic grafts in aneurysm repair. Open repair has been refined since the 1960s, and continues to prove itself to be a durable operation with an excellent track record, with perioperative mortality for open repair of abdominal aortic aneurysms (AAAs) ranging from as low as 1.2% to 3.8%.

With the dawn of a new era in endovascular management of vascular pathology, Parodi reported the first repair of an aortic aneurysm with an aortic stent-graft in 1991. Since then, a rapid transition from open to endovascular repair of AAA may be noticed. In the United States today, data indicates that the majority of AAA repairs are performed via an endovascular approach. Thoracic endografts are also now widely used to treat aneurysms of the thoracic aorta as well as in traumatic disruptions. As endograft technology and endovascular techniques progressed and refined over the 2000s, new innovations including branch and fenestrated endografts allow treatment of complex thoracoabdominal lesions without compromising flow to visceral branches.

## **1.2. Abdominal Aortic Aneurysms**

Abdominal aortic aneurysms account for the majority of aneurysm disease in the body. It usually results from degeneration in the media of the arterial wall, leading to a slow and continuous dilatation of the lumen of the vessel. Other less common causes include infection, cystic medial necrosis, arteritis, trauma, inherited connective-tissue disorders, and anastomotic disruption.

It generally affects the elderly, especially white men. Several risk factors are associated with its development, with smoking being the strongest. Other factors include increased height, weight, body mass index, and body surface area. A genetic component is also present, with familiar clustering been noted in 15-25% of patients undergoing surgical repair of AAA. Negatively associated factors include female sex, African American race, and diabetes mellitus.

## **1.3. Anatomy**

The abdominal aorta has three distinct tissue layers: intima, media, and adventitia. The intima is composed of endothelium in the luminal surface and subendothelial extracellular matrix. The media comprises smooth muscle cells surrounded by elastin, collagen, proteoglycans, and is bounded by the internal and external elastic laminae. This layer accounts for the structural and elastic properties of the artery. The adventitia consists primarily of collagen, loose connective tissue, fibroblasts, capillaries, immunomodulatory cells, and adrenergic nerves.

The diameter of the aorta decreases in size from its thoracic portion to the abdominal and infrarenal portions. There is a change in vessel wall composition, with a reduction in medial elastin layers from the thoracic area to the abdominal portion. There is also a reduction in elastin and collagen content as it progresses from thoracic to abdominal aorta.

AAAs may be described as fusiform, or saccular. Most cases of AAA involve the segment below the renal arteries and just above the iliac arteries. Occasionally it can be located close to the renal arteries (juxtarenal AAA) or involve the renal arteries altogether (pararenal AAA). There can also be associated iliac and hypogastric artery aneurysms as well. These have important anatomic surgical and endovascular considerations, as preservation of these arterial branches is desirable.

#### **1.4. Pathophysiology**

AAA is primarily a degenerative condition resulting from a failure of the major structural proteins of the aorta. Biochemical studies have shown decreased quantities of elastin and collagen but an increased ratio of collagen to elastin in aneurysm walls. AAA develops following degeneration of the media, ultimately leading to widening of the vessel lumen and loss of structural integrity.

There has been significant debate regarding the cause and pathophysiology of AAA development. More than 90% of the AAA's are associated with atherosclerosis and this has traditionally been considered as the primary cause. However, although atherosclerosis is uniformly present in aneurysm walls and it shares common risk factors with occlusive atherosclerosis, the concept of atherosclerosis as the sole contributor to AAA development has been challenged. There are indications that more factors other than atherosclerosis may be involved in AAA development. Most patients with aneurysmal disease do not have concomitant aortoiliac femoral atherosclerotic occlusive disease. This has seriously challenged the long held theory of atherosclerosis causing vessel wall weakening leading to aneurysmal degeneration. Many authors suggest that atherosclerosis might be a coincidental or a facilitating process rather than a primary cause for aneurysmal disease.

Studies have identified multiple processes involved in the development of AAA, including proteolytic degradation of aortic wall connective tissue, inflammation and immune responses, biomechanical wall stress, and genetic modulation. Surgical specimens of AAA have also revealed inflammation, infiltration of lymphocytes and macrophages, thinning of the media; and marked loss of elastin.

Elastin is the main load-bearing element in the aorta. The number of medial elastin layer decreases markedly as one progresses from proximal thoracic aorta to the infrarenal aorta. In aneurysm walls, elastin degeneration and fragmentation have been observed.

Proteolysis of the aortic media in AAA has been observed. There is a relative increase in proteolytic enzymes to their inhibitors in the abdominal aorta with age. The role of metalloproteinases (MMP) in tissue remodeling has also been implicated. Reports have found increased expression and activity of this enzyme in individuals with AAA. MMP and other proteases are secreted into the extracellular matrix by macrophages and smooth muscle cells. Although MMP is responsible for vessel wall remodeling in normal aortic tissue, in AAA, there is increased MMP activity relative to its inhibitor activity, leading to net degradation of elastin and collagen.

AAA is also an inflammatory state, whereby a chronic adventitial and medial inflammation is present on histological examination. Lymphocyte and macrophage infiltration of the vessel wall in AAA release various cytokines, particularly IL1, 6, 8 and TNF- $\alpha$ , all of which can trigger protease activation.

### **1.5. Etiology**

Patients at greatest risk for AAA are men older than 65 years with peripheral atherosclerotic vascular disease and history of smoking. The US Preventive Services Task Force recommends ultrasonography screening in men aged 65-75 years who have ever smoked.

Risk factors include:

- Hypertension
- Chronic obstructive pulmonary disease (COPD)
- Previous aneurysm repair or peripheral aneurysm (popliteal or femoral)
- Coronary artery disease
- Family history of aneurysm disease

Less frequent causes include:

- Marfan syndrome
- Ehlers-Danlos syndrome
- Collagen-vascular disease
- Mycotic aneurysms
- Cystic medial necrosis
- Arteritis
- Trauma
- Anastomotic disruption
- Pseudoaneurysms

### **1.6. Diagnosis**

- 1) History including family history
- 2) Physical examination
- 3) Ultrasound; useful in screening and follow up evaluation
- 4) CT (Computed Tomography) Scan
- 5) CTA (Computed Tomographic Angiogram); for definite management plan
- 6) MRA (Magnetic resonance angiogram)
- 7) Angiogram; as a part of preoperative plan and management

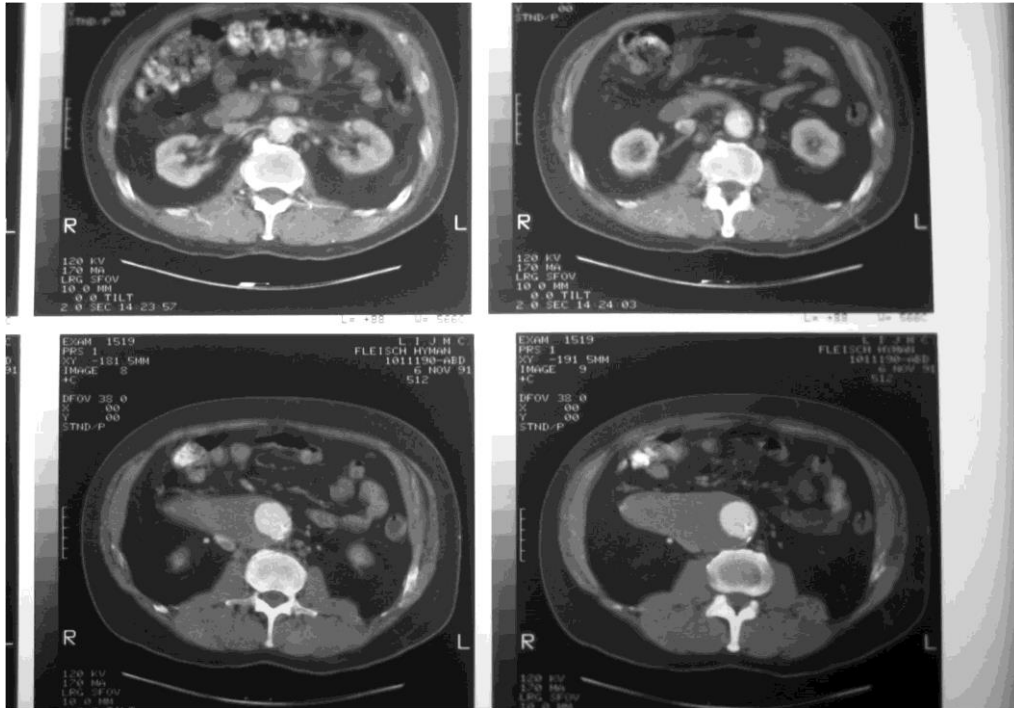


Figure 1. An example of a CT Scan

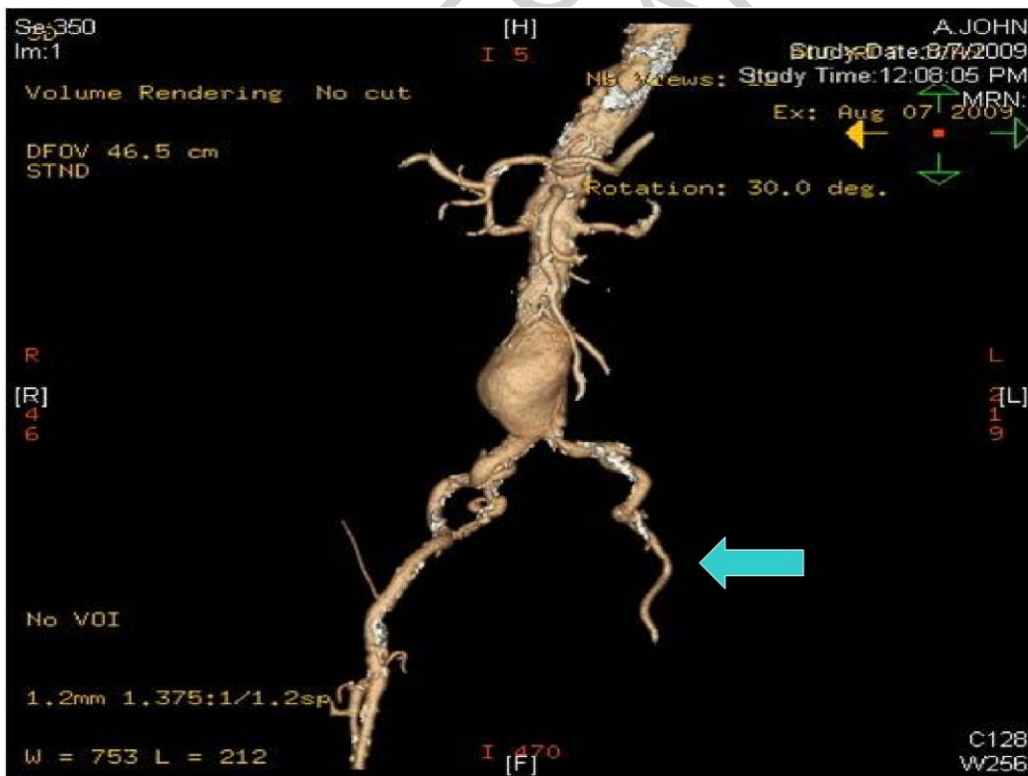


Figure 2. CTA with 3-dimensional reconstruction (arrow indicating occlusive disease at left iliac artery).

## 1.7. Surgical Treatment

Preoperative evaluation of the patient with AAA should include medical optimization of cardiac, pulmonary, renal disease, trans-thoracic echo, and further cardiac work up depending on the risk factors.

For imaging of AAA modalities, available are duplex ultrasonography (DUS), computerized tomography (CT), aortography, and magnetic resonance imaging (MRI). Spiral CT with intravenous (IV) contrast offers accurate preoperative assessment of aneurysm size, morphology, extent, and overall suitability for endovascular repair. Advantages of MRI over CT are no ionizing radiation, and possible sparing of potentially nephrotoxic contrast agents.

## 1.8. Indications for Repair

1. All patients with symptomatic AAA (abdominal or back pain), regardless of the size
2. All patients with known or suspected rupture
3. Asymptomatic patients with AAA diameter 5.5cm in men, and 5.0cm in women or larger.
4. Asymptomatic patients with AAA that has grown 0.5cm or more over a period of 6 months.

-  
-  
-

TO ACCESS ALL THE 35 PAGES OF THIS CHAPTER,  
Visit: <http://www.eolss.net/Eolss-sampleAllChapter.aspx>

## Bibliography

### References

Blankensteijn JD, de Jong SE, Prinssen M, van der Ham AC, Buth J, van Sterkenburg SMM, Verhagen HJM, Buskens E, Grobbee DE. (2005) Two-year outcomes after conventional or endovascular repair of abdominal aortic aneurysms. *N Engl J Med*; 352:2398. [A multicenter, randomized trial comparing open repair with endovascular repair of abdominal aortic aneurysm]

Connors MS, Sternbergh WC, Carter G, Tonnessen BH, Yoselevitz M, Money SR. (2002) Endograft migration one to four years after endovascular abdominal aortic aneurysm repair with the AneuRx device: a cautionary note. *J Vasc Surg*; 36:476-484. [Midterm complication of a particular device used for endovascular repair of abdominal aortic aneurysm]

Criado FJ, Wilson EP, Fairman RM, Abul-Khoudoud O, Wellons E. (2001) Update on the Talent aortic stent-graft: a preliminary report from the United States phase I and II trials. *J Vasc Surg*;33:S146-S149. [Initial report on the safety and efficacy of the Talent aortic stent-graft (Medtronic World Medical, Sunrise, Fla) in the treatment of infrarenal abdominal aortic aneurysms]

Criado FJ, Clark NS, McKendrick C, Longway J, Domer GS.. (2003) Update on the Talent LPS AAA stent graft: results with "Enhanced Talent." *Semin Vasc Surg*; 16:158-165. [Follow up report on the results of Talent aortic stent-graft in the endovascular treatment of infrarenal abdominal aortic aneurysms]

De Bruin JL, Baas AF, Buth J. (2010) Long-term outcome of open or endovascular repair of abdominal aortic aneurysm; *N Engl J Med*;362:1881-9. [Six year results of a multicenter, randomized, controlled trial comparing open repair with endovascular repair of abdominal aortic aneurysm]

EVAR trial participants. (2005) Endovascular aneurysm repair and outcome in patients unfit for open repair of abdominal aortic aneurysm (EVAR trial 2): randomized controlled trial. *Lancet*; 365: 2187. [A landmark article comparing endovascular repair of abdominal aortic aneurysm to no intervention in patients unfit for open repair of abdominal aortic aneurysm]

Giles K, Pomposelli F, Hamdan A. (2009) Decrease in total aneurysm-related deaths in the era of endovascular aneurysm repair. *J Vasc Surg*; 49:543-550. [This mentions that since the introduction of EVAR, the annual number of deaths from intact and ruptured AAA has significantly decreased]

Greco G, Egorova N, Anderson PL. (2006) Outcomes of endovascular treatment of ruptured abdominal aortic aneurysms. *J Vasc Surg*;43:453-459. [This shows results of endovascular repair of abdominal aortic aneurysm in patients who had rupture]

Greenberg R. (2003) The Zenith endograft for abdominal aortic aneurysms: clinical update. *Semin Vasc Surg* ;16:151-157. [Results of a particular device used for endovascular repair of abdominal aortic aneurysm]

Greenhalgh RM, Brown LC, Kwong GP, Powell JT, Thompson SG. (2004) Comparison of endovascular aneurysm repair with open repair in patients with abdominal aortic aneurysm (EVAR trial 1), 30-day operative mortality results: randomised controlled trial. *Lancet*; 364: 843. [A landmark article comparing endovascular repair of abdominal aortic aneurysm to open repair]

Greenhalgh RM, Brown LC, Powell JT. (2005) Endovascular aneurysm repair versus open repair in patients with abdominal aortic aneurysm (EVAR trial 1): randomized controlled trial. *Lancet* ; 365: 2179. [Follow up on the previous article comparing endovascular repair of abdominal aortic aneurysm to open repair]

Greenhalgh RM, Brown LC, Powell JT. (2010) Endovascular versus open repair of abdominal aortic aneurysm; United Kingdom EVAR Trial Investigators. *N Engl J Med*;362: 1863-71. [Long term results of the article comparing endovascular repair of abdominal aortic aneurysm to open repair]

Hacker R, DeMarco Garcia L, Siegel D, Kissin M, Schutzer W, Chang JB. (2011) Nonresective repair for abdominal aortic aneurysm. *Ann Vasc Surg*; 25: 58 e1-558e4. [This describes a surgical technique for patient unfit for any major surgery and not suitable for endovascular repair of abdominal aortic aneurysm]

Harris PL, Vallabhaneni SR, Desgranges P, Becquemin J-P, van Marrewijk C, Laheij RJF. (2000) Incidence and risk factors of late rupture, conversion, and death after endovascular repair of infrarenal aortic aneurysms: the EUROSTAR experience. European Collaborators on Stent/graft techniques for aortic aneurysm repair. *J Vasc Surg*; 32:739. [Medium term results of European Collaborators on Stent/graft techniques for aortic aneurysm repair registry]

Laheij RJ, Buth J, Harris PL, Moll FL, Stelter WJ, Verhoeven ELG. (2000) Need for secondary interventions after endovascular repair of abdominal aortic aneurysms. Intermediate-term follow-up results of a European collaborative registry (EUROSTAR) *Br J Surg*; 87:1666. [Intermediate-term follow-up results of European Collaborators on Stent/graft techniques for aortic aneurysm repair registry]

Lederle FA, Kane RL, MacDonald R. (2007) Systematic review: repair of unruptured abdominal aortic aneurysm. *Ann Intern Med*;146:735. [This is a review article analyzing other trials to summarize current effectiveness of treatment options, including active surveillance, open repair, and endovascular repair, for unruptured AAAs]

Matsumura JS, Brewster DC, Makaroun MS, Naftel DC. (2003) Excluder Bifurcated Endoprosthesis Investigators: A multicenter controlled clinical trial of open versus endovascular treatment of abdominal aortic aneurysm. *J Vasc Surg*; 37:262-271. [Results of a particular device used for endovascular repair of abdominal aortic aneurysm]



Politz JK, Newman VS, Stewart MT. (2000): Late abdominal aortic aneurysm rupture after AneuRx repair: report of three cases. *J Vasc Surg*; 31: 599-606. [Late complication of a particular device used for endovascular repair of abdominal aortic aneurysm]

Prinssen M, Verhoeven EL, Buth J, Cuypers, PWM, van Sambeek MRHM, Balm R, Buskens E, Grobbee DE, Blakensteijn JD. (2004) A randomized trial comparing conventional and endovascular repair of abdominal aortic aneurysms. *N Engl J Med*; 351:1607. [Results of Dutch Randomized Endovascular Aneurysm Management (DREAM) Trial Group]

Sternbergh WC, Money SR, Greenberg RK, Chuter, TAM. (2004) Zenith Investigators: Influence of endograft oversizing on device migration, endoleak, aneurysm shrinkage, and aortic neck dilation: results from the Zenith multicenter trial. *J Vasc Surg*; 39:20-26. [This outlines the influencing factors leading to late complications of endovascular repair of abdominal aortic aneurysm with a particular device]

Teufelsbauer H, Prusa AM, Wolff K, Polteraue P, Nanobashvili J, Prager M, Hölzenbein T, thurnher S, Lammer J, Schempere M, Kretschmer G, Huk I. (2002) Endovascular stent grafting versus open surgical operation in patients with infrarenal aortic aneurysms: a propensity score-adjusted analysis. *Circulation* ; 106:782. [A study trying to identify comorbid conditions that could be direct indication of endovascular repair of abdominal aortic aneurysm]

White RA. (1999) AneuRx trial data presented to the FDA. Abstract and presentation at the annual meeting of the European Society for Vascular Surgery, Copenhagen, September 4, 1999. [Very early results of a particular device used for endovascular repair of abdominal aortic aneurysm]

Zarins CK, White RA, Schwarten D, Kinney E, Diethrich EB, Hodgson KJ, Fogarty TJ. (1999) Investigators of the AneuRx Trial: Aneurysm stent graft versus open surgical repair of abdominal aortic aneurysms: multicenter prospective clinical trial. *J Vasc Surg*; 29:292-308. [Early results of a particular device used for endovascular repair of abdominal aortic aneurysm comparing open vs endovascular approach]

Zarins CK, White RA, Fogarty TJ. (2000a) Aneurysm rupture after endovascular repair using the AneuRx stent graft. *J Vasc Surg*; 31:960-970. [Description of complication of a particular device used for endovascular repair of abdominal aortic aneurysm]

Zarins CK, White RA, Hodgson KJ, Schwarten D, Fogarty TJ. (2000b) AneuRx Clinical Investigators: Endoleak as a predictor of outcome after endovascular aneurysm repair: AneuRx multicenter clinical trial. *J Vasc Surg* ; 32:90-107. [Details of how an early small finding can predict delayed complication of a particular device used for endovascular repair of abdominal aortic aneurysm]

Zarins CK, White RA, Moll FL, Crabtree T, Bloch DA, Hodgson KJ, Fillinger MF, Fogarty TJ. (2001c) The AneuRx stent graft: four-year results and worldwide experience. *J Vasc Surg*; 33:S135-S145. [Midterm worldwide results of a particular device used for endovascular repair of abdominal aortic aneurysm]

### **Biographical Sketches**

**Chuo Ren Leong, M.D.** is a senior vascular surgery fellow at the Northshore-LIJ Healthcare System in Manhasset, New York. He is a graduate of McGill University Faculty of Medicine, Montreal, Canada. He has completed his general surgery residency at the Northshore LIJ Healthcare System, where he also served as administrative chief resident.

**Rajeev Gupta, MBBS, MS, MRCS** is a fellow in vascular surgery at Northshore-LIJ Healthcare System, New Hyde Park, New York. He graduated from Sawai Man Singh Medical College, Jaipur, India where he did his surgical training. He did further training in the UK and obtained Membership in the Royal College of Surgeons of Edinburgh. He has published many articles in journals, and is reviewer of many journals, e.g., *Annals of Surgery*, *Annals of The Royal College of Surgeons of England*, and the *European Journal of Vascular and Endovascular Surgery*.

**Mark Kissin, M.D., F.I.C.A.** is Assistant Professor, Hofstra Northshore-LIJ School of Medicine, Uniondale, New York. He is Attending Vascular Surgeon at Northshore-LIJ Healthcare System, New Hyde Park, New York.

**Robert W. Chang, M.D., F.A.C.S.** is a board certified vascular and endovascular surgeon. He is a member of the Society for Vascular Surgery, a fellow of the American College of Surgeons as well as the San Francisco and Yale Surgical Societies. He completed his surgical residency at Yale-New Haven Hospital in New Haven, Connecticut, and his vascular fellowship at Dartmouth-Hitchcock Medical Center in Lebanon, New Hampshire. He has authored numerous book chapters, peer-reviewed articles, and presented his work many times throughout his surgical career. He lives in San Francisco, California, and practices vascular and endovascular surgery in a large multispecialty group.

**John B. Chang, M.D., F.A.C.S., F.I.C.A.** is a board certified vascular surgeon working as teaching faculty at a major university affiliated teaching institution, Northshore-LIJ Health Care System in New York, teaching medical students, interns, residents, and fellows. His practice includes open and endovascular procedures. His academic appointments include Professor of Clinical Surgery, Hofstra Northshore-LIJ School of Medicine, Hofstra University, Uniondale, New York, and Professor of Clinical Surgery, Albert Einstein College of Medicine, Yeshiva University, Bronx, New York. He currently serves as Director, Long Island Vascular Center, Roslyn, New York; Chairman, Board of Directors, International College of Angiology, Inc.; Editor-in-Chief, *International Journal of Angiology*, and Founding Chairman, Asian Society for Vascular Surgery. He has authored numerous books including the first English written *Textbook of Angiology*, and published many articles on the management of patients with vascular diseases. He has received numerous citations and awards for his work in the field of angiology and vascular surgery.